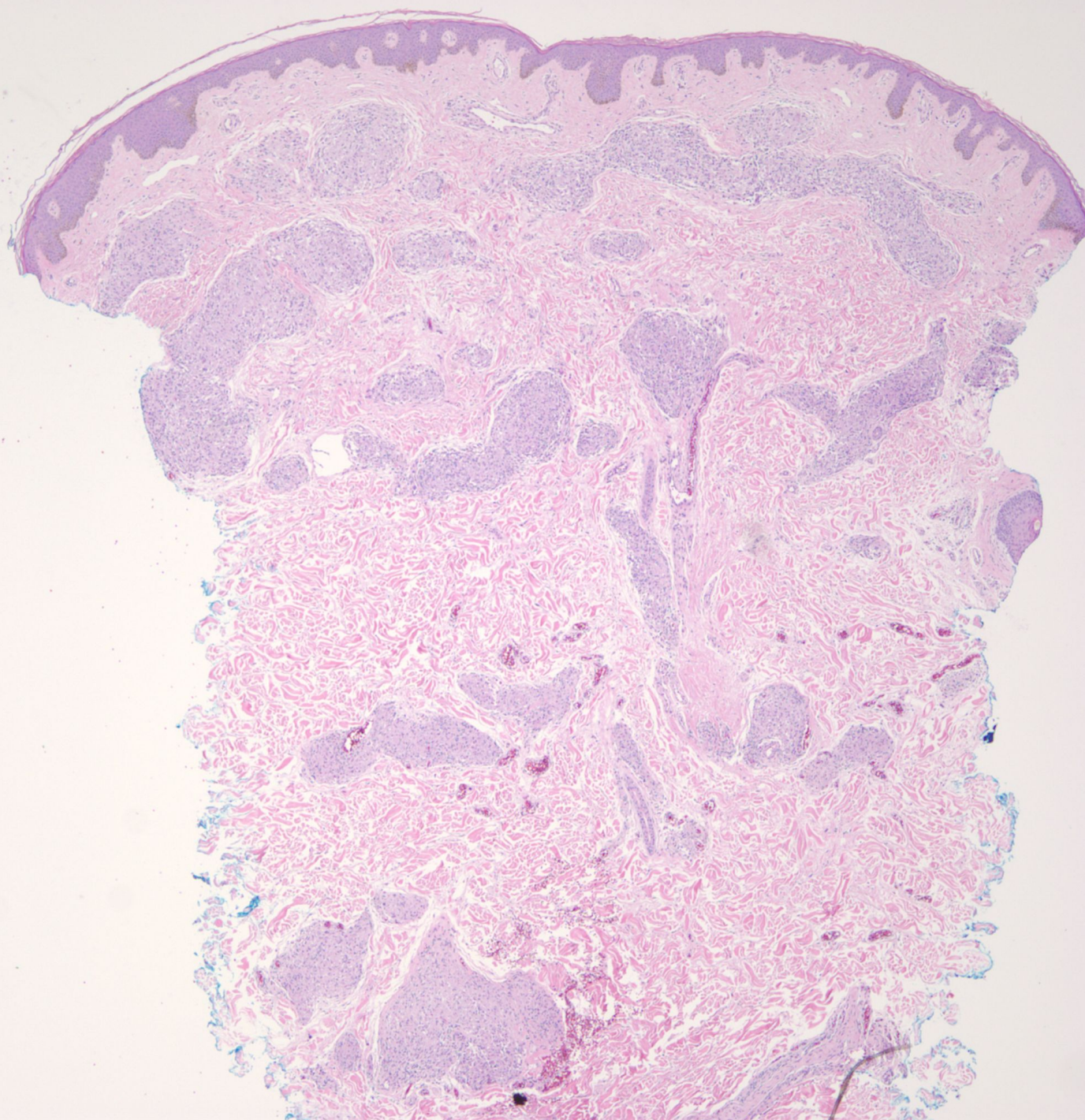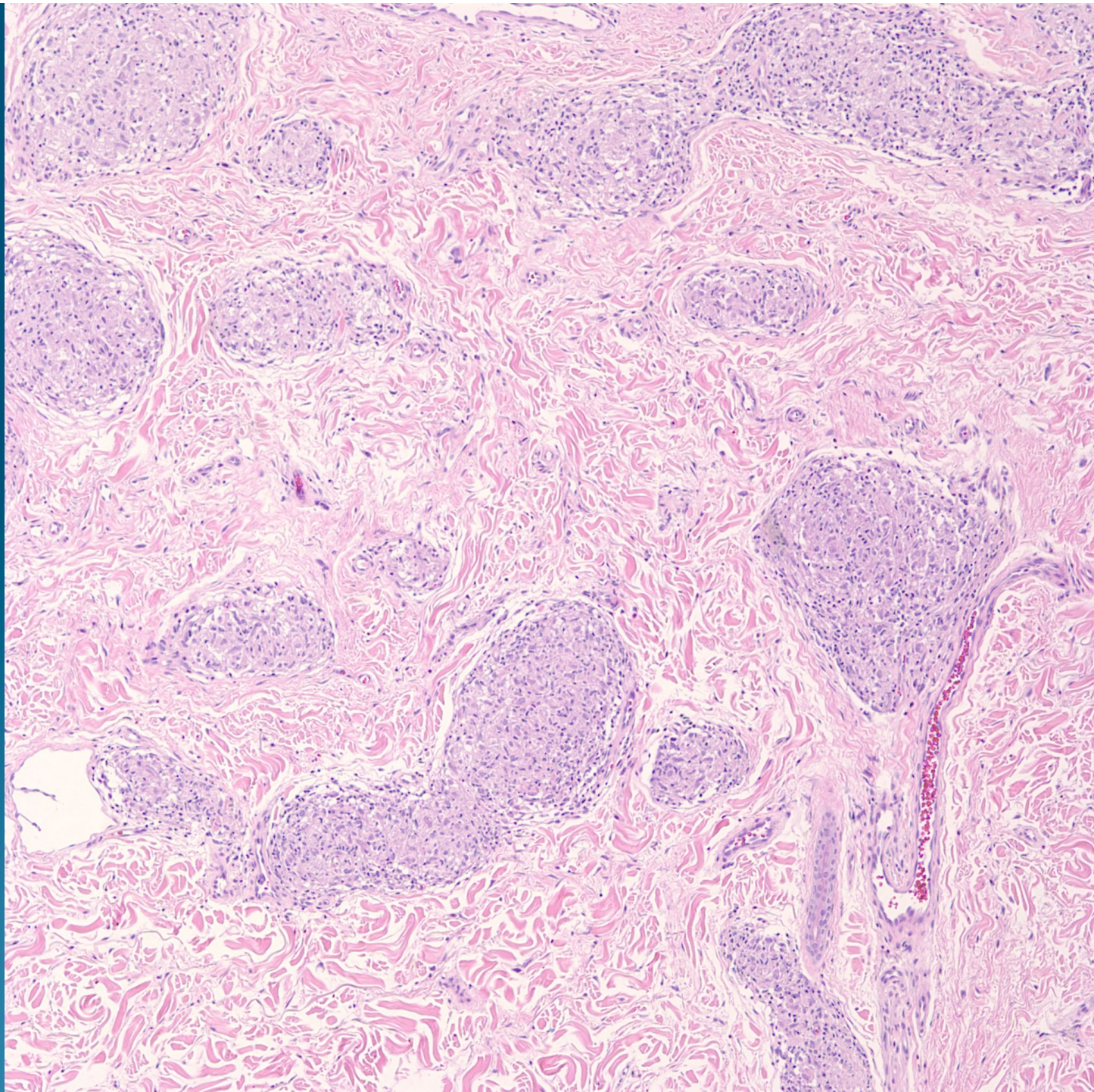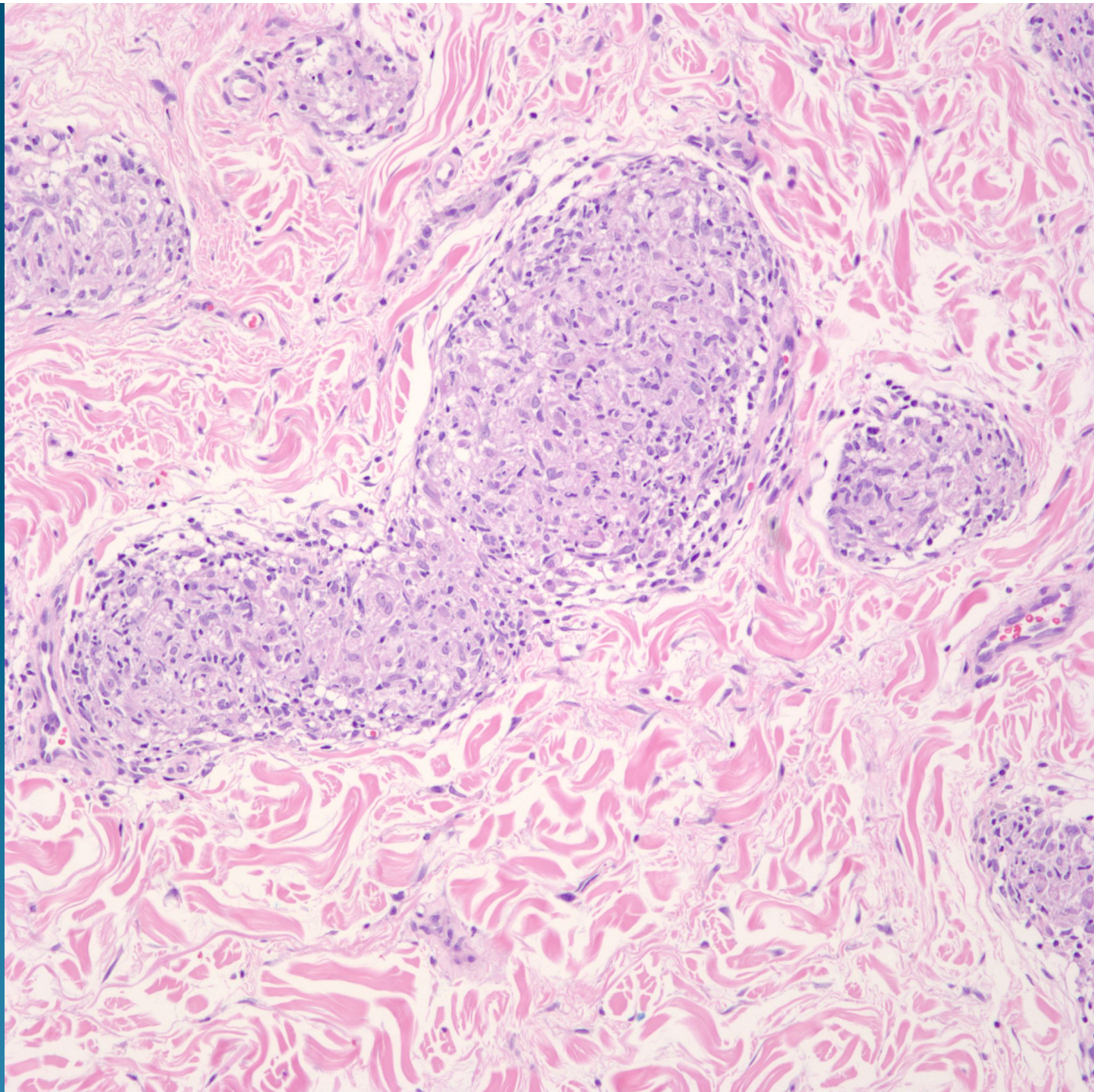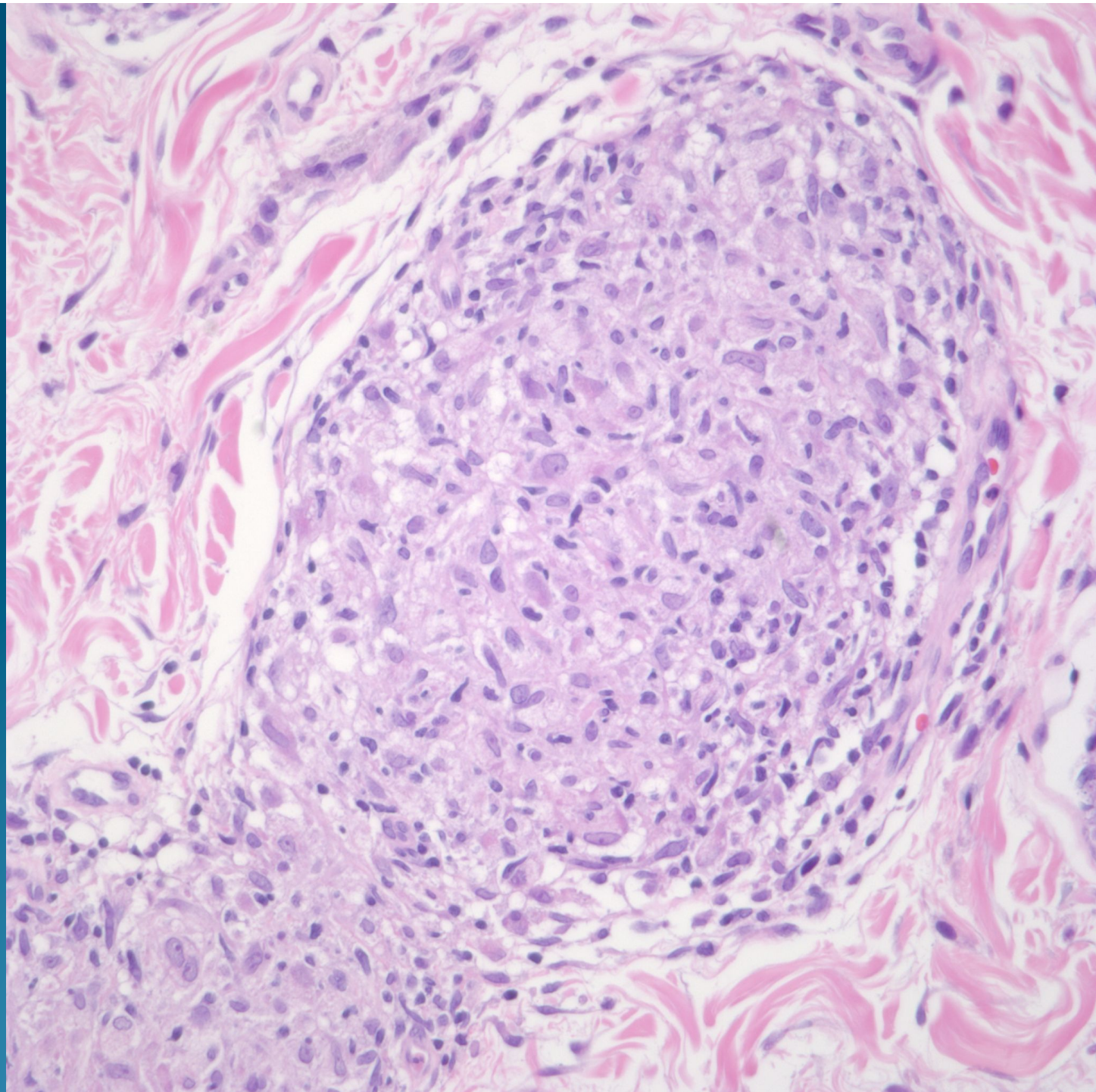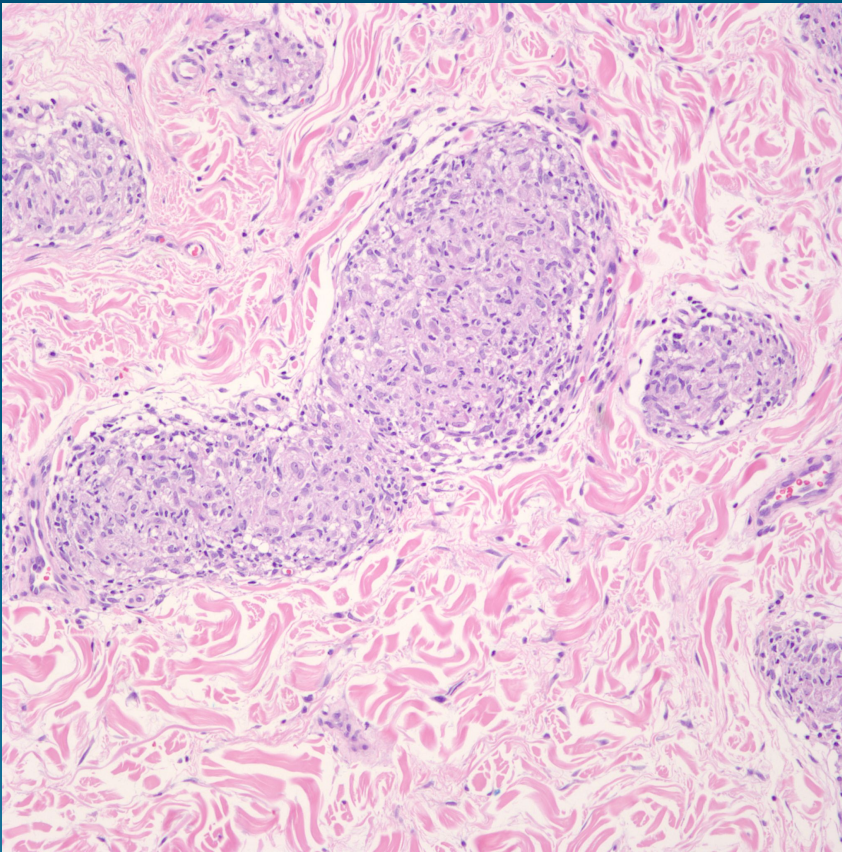


What is the best diagnosis?

- A. Sarcoidosis
- B. Langherans cell histiocytosis
- C. Granulomatous slack skin disease
- D. Granuloma annulare
- E. Necrobiosis xanthogranuloma

Sarcoidosis

Pearls



- Non caseating granulomas with minimal surrounding inflammatory cell infiltrate (“naked granulomas”)
- Always polarize to rule out sarcoidal foreign body reaction-However, if found, it does not exclude an underlying systemic sarcoidosis
- Rule out infection, need Acid fast, FITE, PAS/GMS